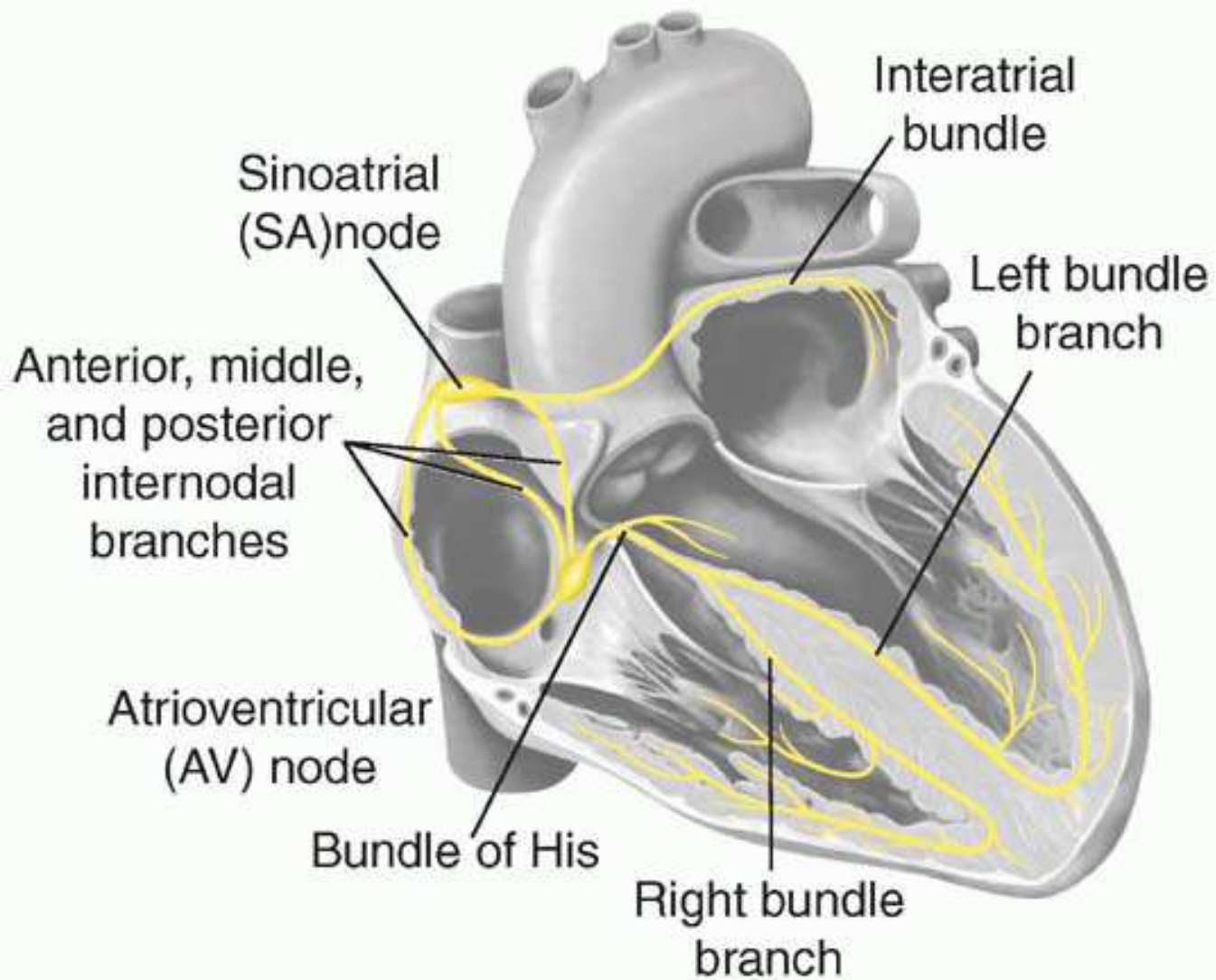
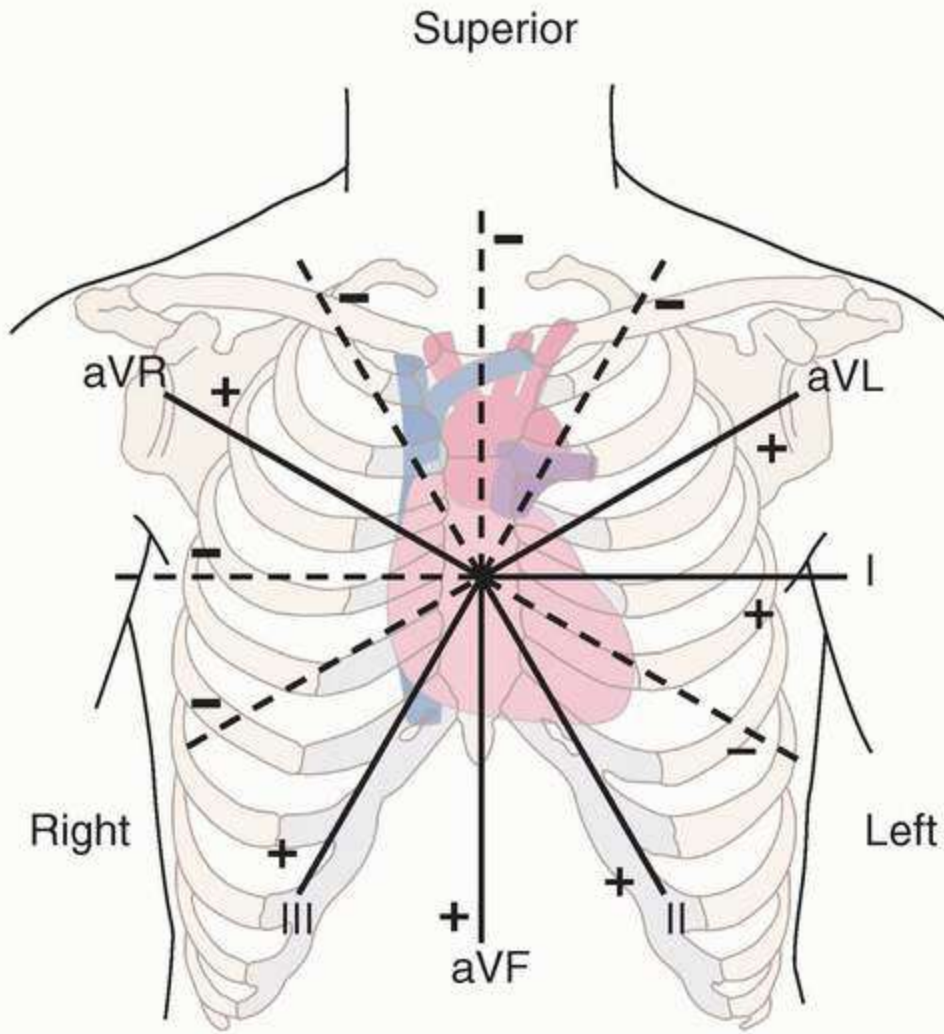
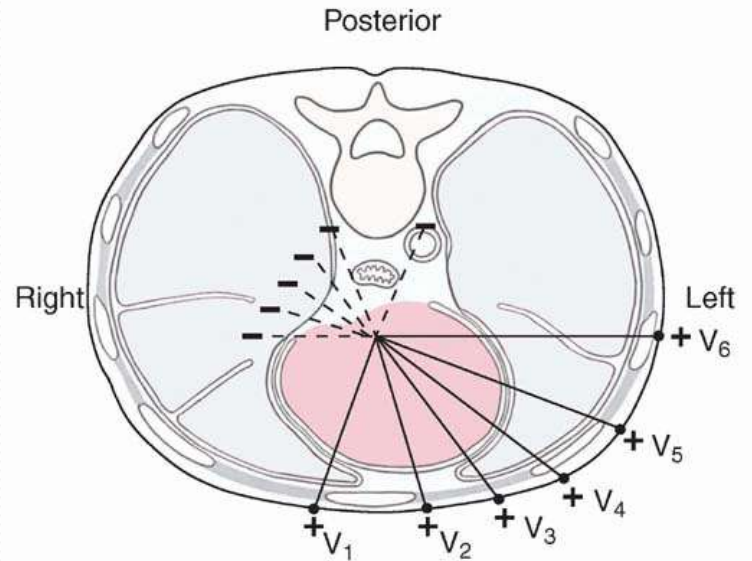


ECG EXERCISES

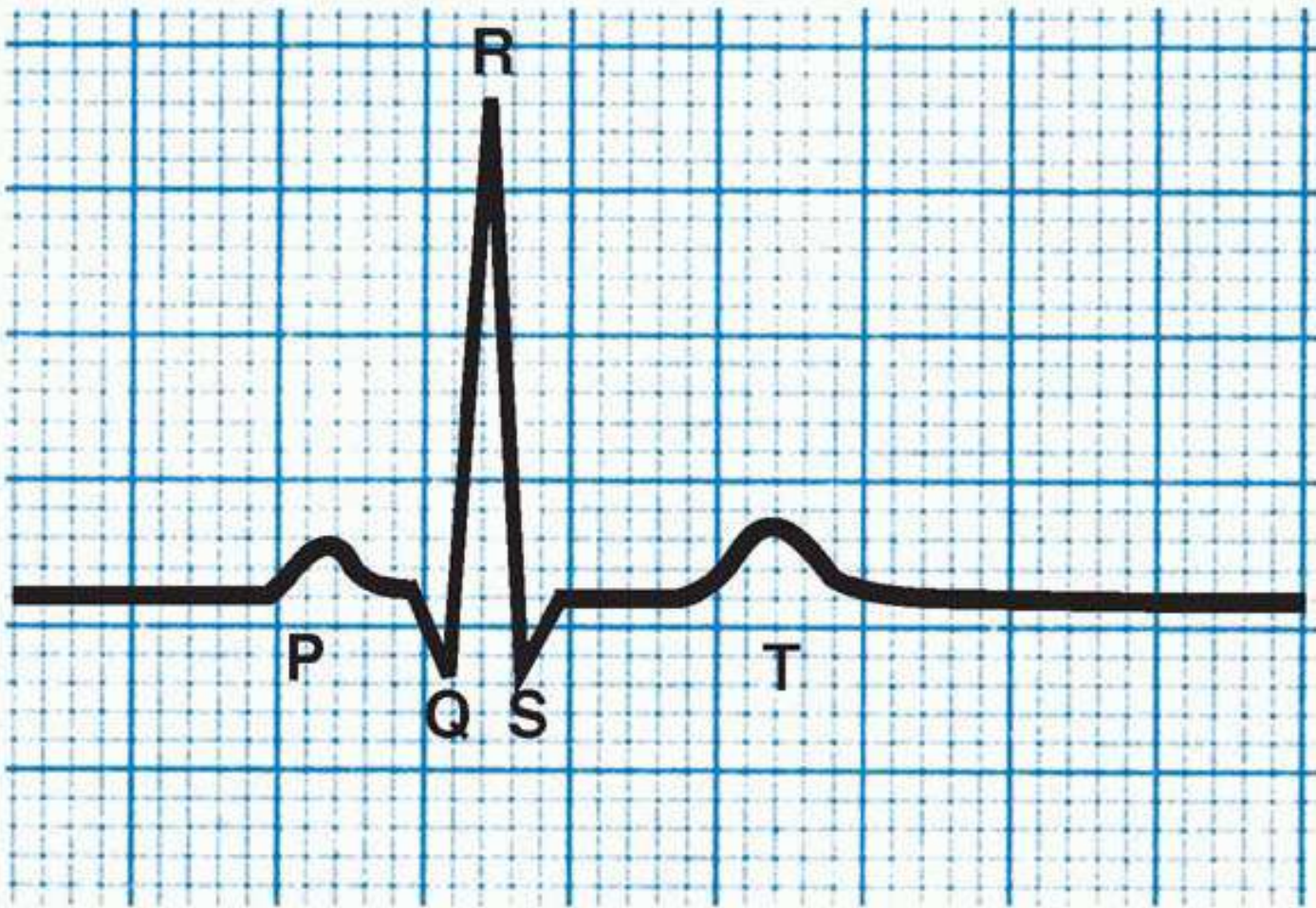




LIMB LEADS: FRONTAL PLANE



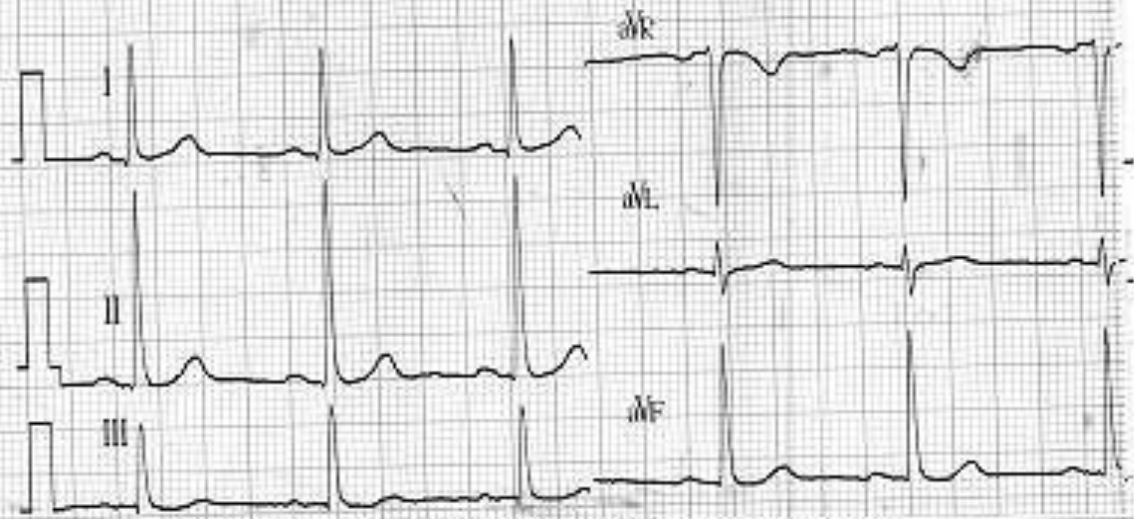
CHEST LEADS: TRANSVERSE PLANE



Jan-5-2011 13:07:11

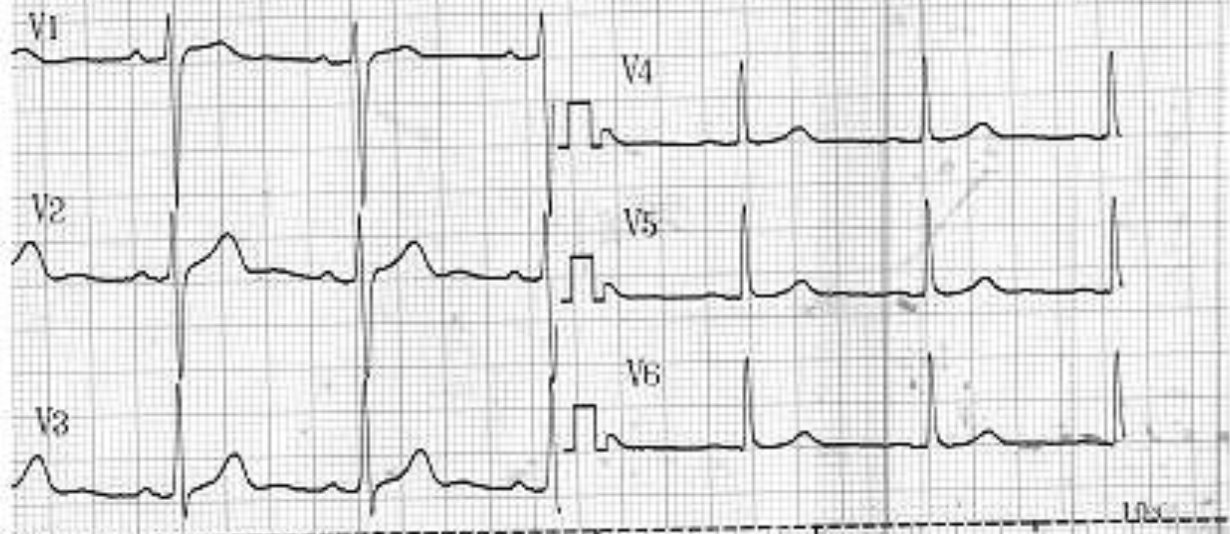
ID:

Female 55 years



Jan-5-2011 13:07:11

Name: SANCHEZ, Josefina OP Dr Javelosa
HE: 88

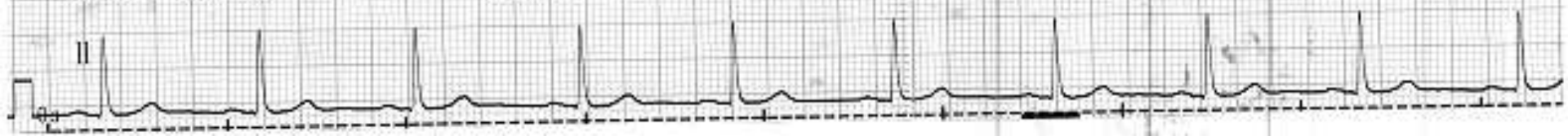



10mm/mV 25mm/s

10mm/mV

10mm/mV

5mm/mV

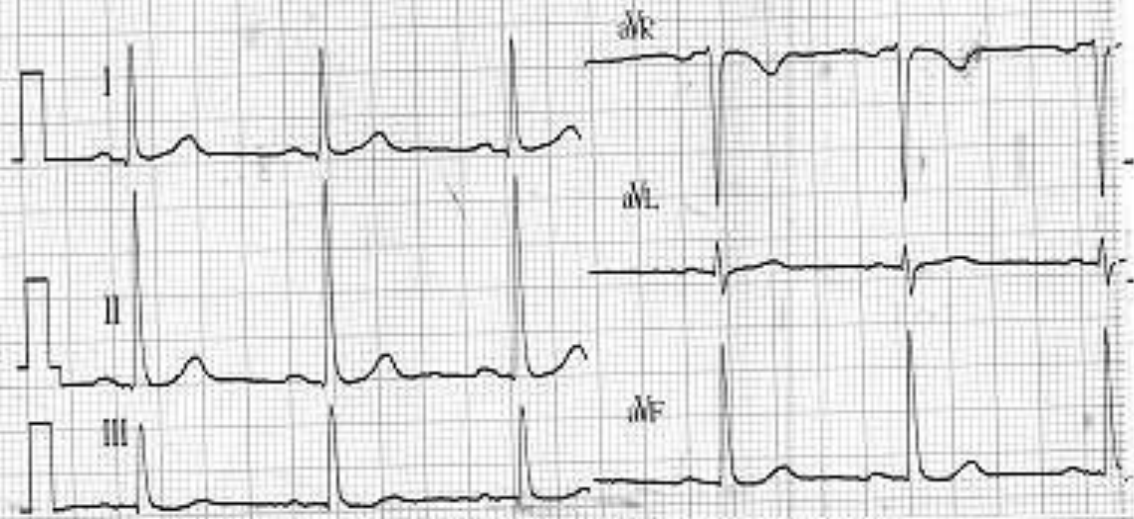


- 
- RATE
 - RHYTHM
 - AXIS
 - (INTERVAL)
 - HYPERTROPHY
 - INFARCTION

Jan-5-2011 13:07:11

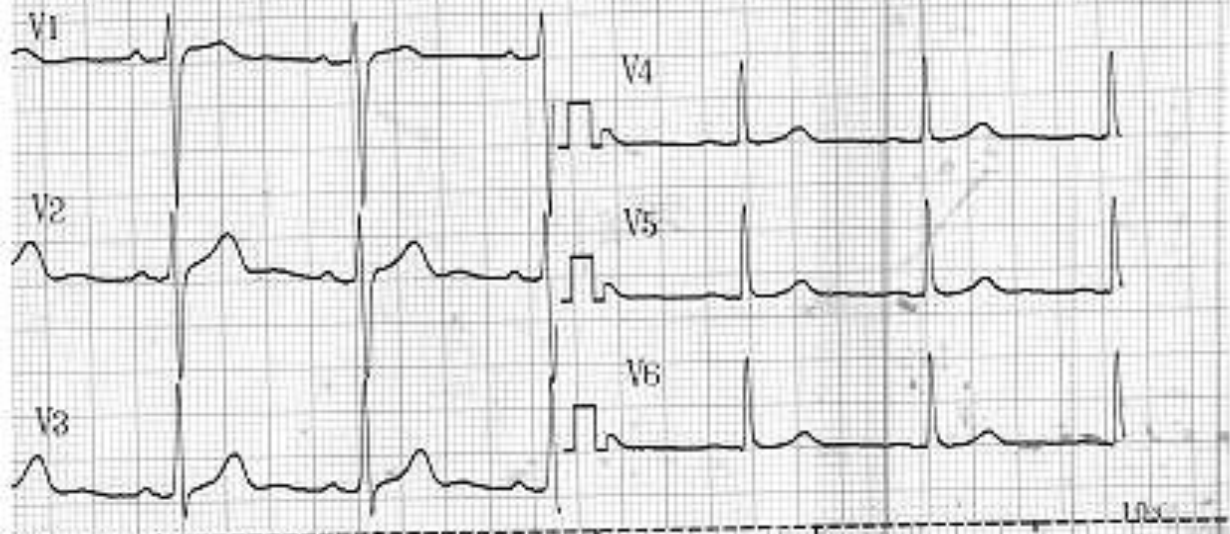
ID:

Female 55 years



Jan-5-2011 13:07:11

Name: SANCHEZ, Josefina OP Dr Javelosa
HE: 88

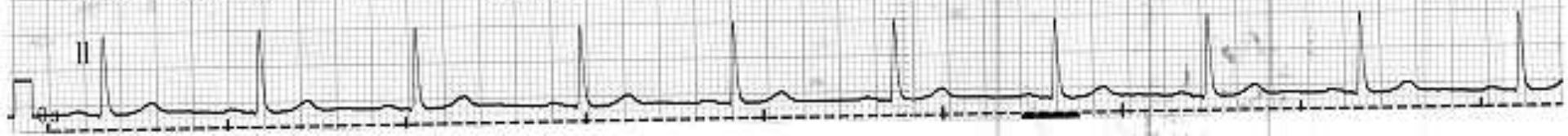



10mm/mV 25mm/s

10mm/mV

10mm/mV

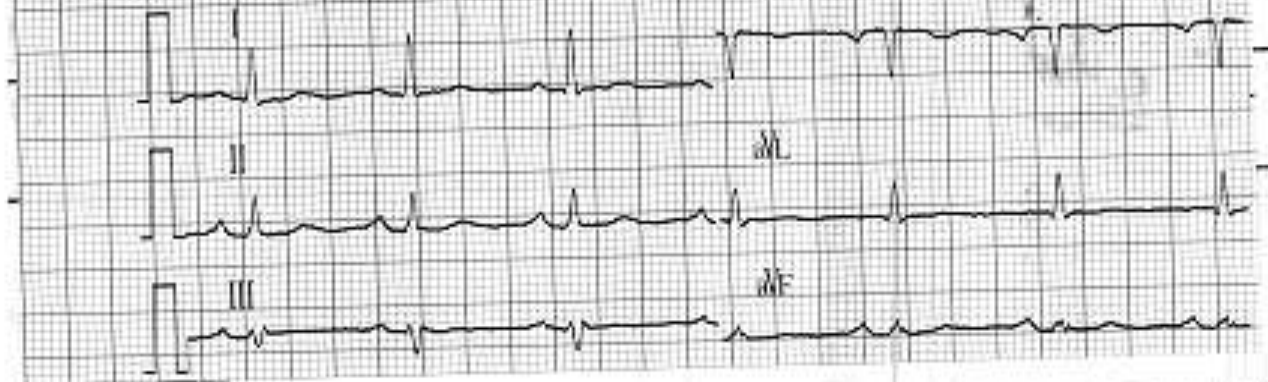
5mm/mV



- 
- RATE – 75BPM
 - RHYTHM - NORMAL
 - AXIS - NORMAL
 - (INTERVAL)
 - HYPERTROPHY - NONE
 - INFARCTION - NONE

Feb 15 2011 15:51:08 ID:

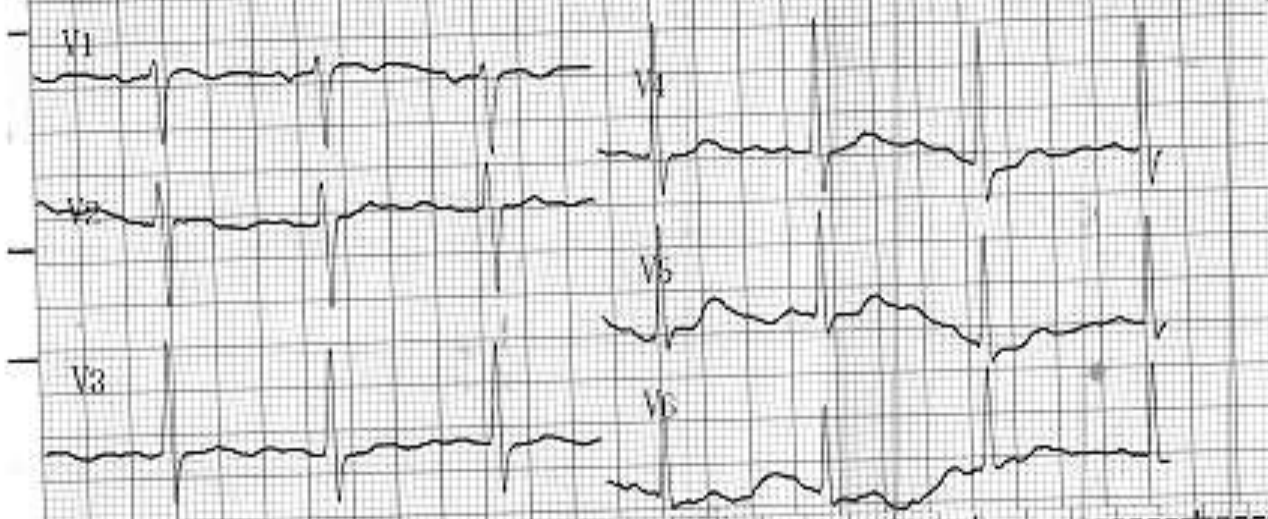
Royo, Ester Modiales 56/4
aR



Feb 15 2011 15:51:09

Name:

HR: 51

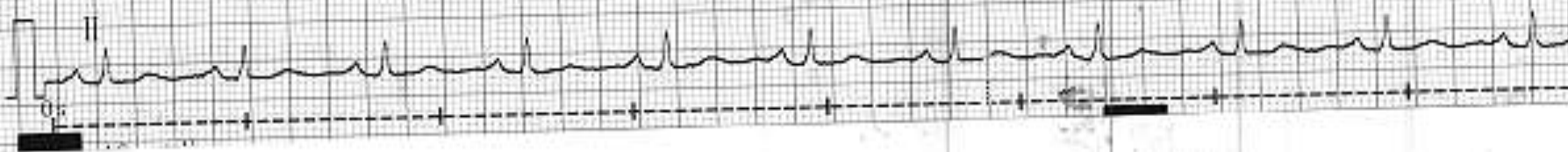


10mm/mV 25mm/s

10mm/mV

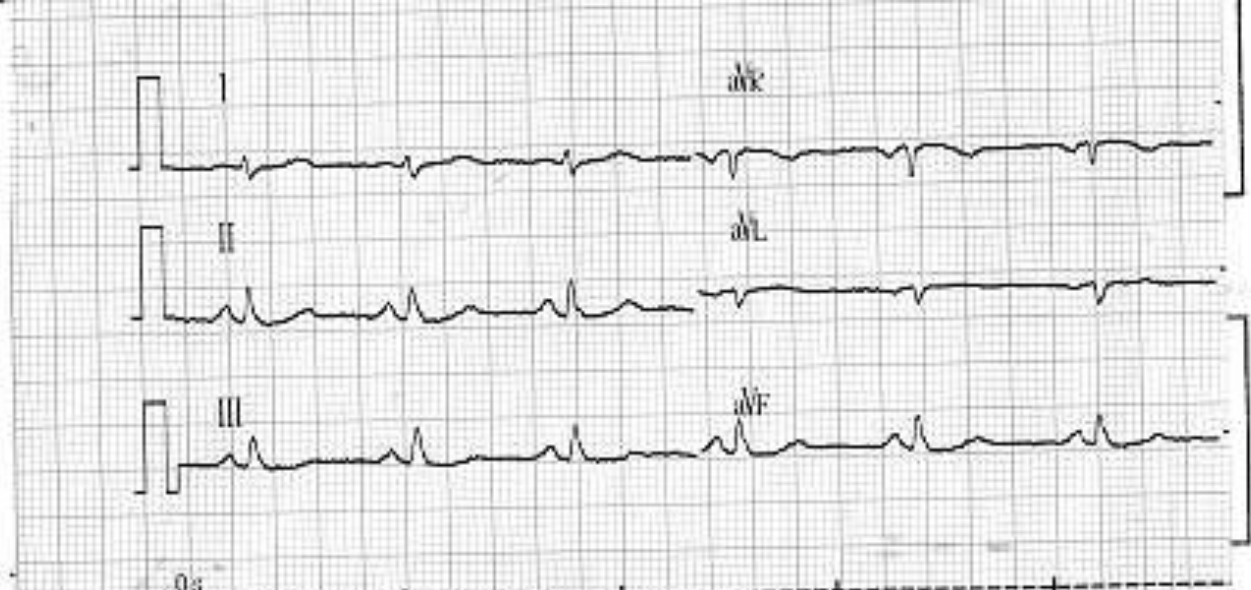
10mm/mV

10mm/mV



- RATE – 68bpm
- RHYTHM – normal sinus
- AXIS - normal
- (INTERVAL)
- HYPERTROPHY - none
- INFARCTION - none

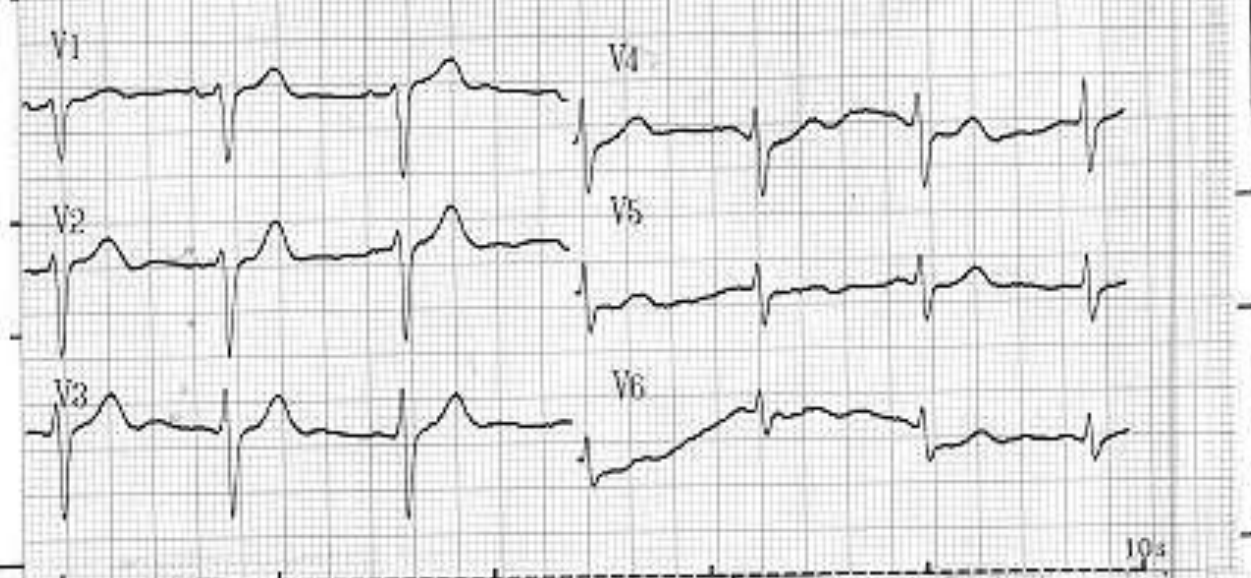
- 
- CONCLUSION:
 - WITHIN NORMAL LIMITS



0s
Jan-15-2011 22:18:11

Name:

HR: 76



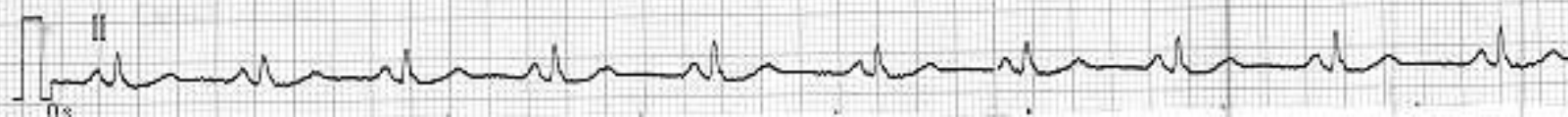
10mm/mV

25mm/s

10mm/mV

10mm/mV

10mm/s



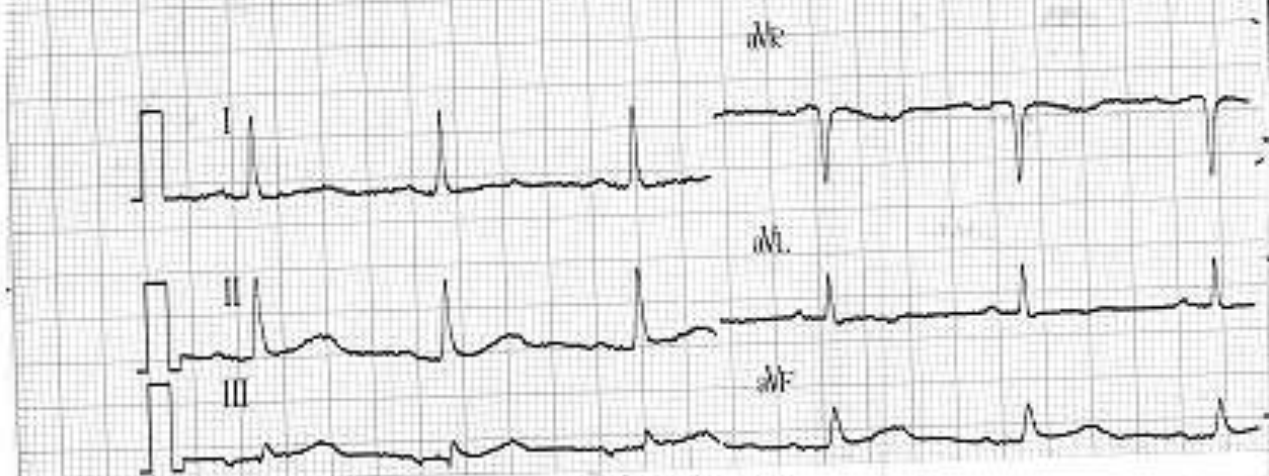
- RATE – 83bpm
- RHYTHM – normal sinus
- AXIS - normal
- (INTERVAL)
- HYPERTROPHY - none
- INFARCTION - none

- 
- CONCLUSION:
 - WITHIN NORMAL LIMITS

Jan-16-2011 21:53:06

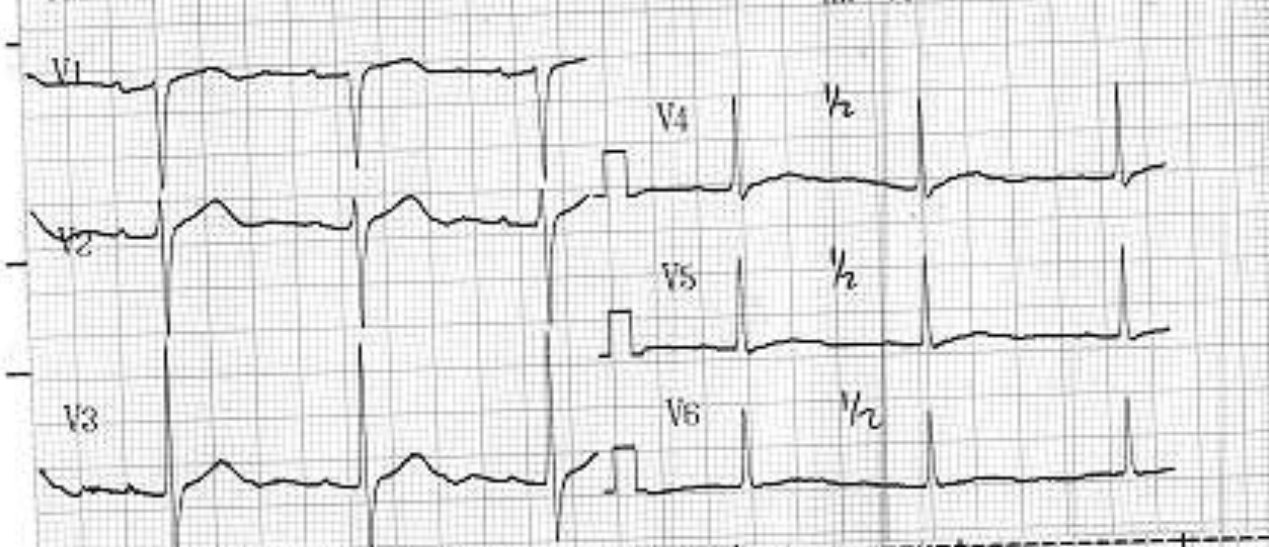
ID:

Female 50 years



Jan-16-2011 21:53:06

Name: TOVILLO, Eufalia Tejaditta ER
HR: 70



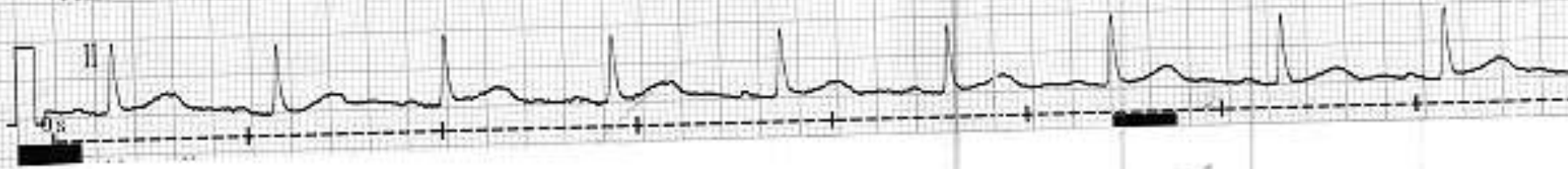10mm/mV

25mm/s

10mm/mV

10mm/mV

5mm/mV



- RATE – 75bpm
- RHYTHM – normal sinus
- AXIS – normal axis
- (INTERVAL)
- HYPERTROPHY - none
- INFARCTION - none

- 
- CONCLUSION:
 - WITHIN NORMAL LIMITS

aVR

aVL

aVF

0s
1.69140
HR: 112

V1

V4

1/2

1/2

V2

V5

1/2

1/2

V3

V6

1/2

1/2

10mm/mV

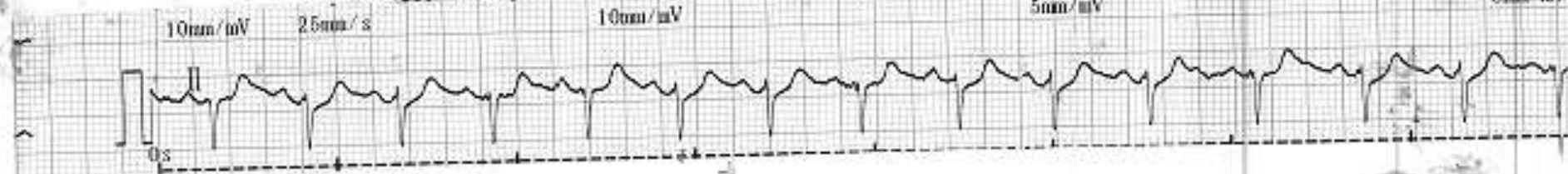25mm/s

10mm/mV

5mm/mV

5mm/mV

0s

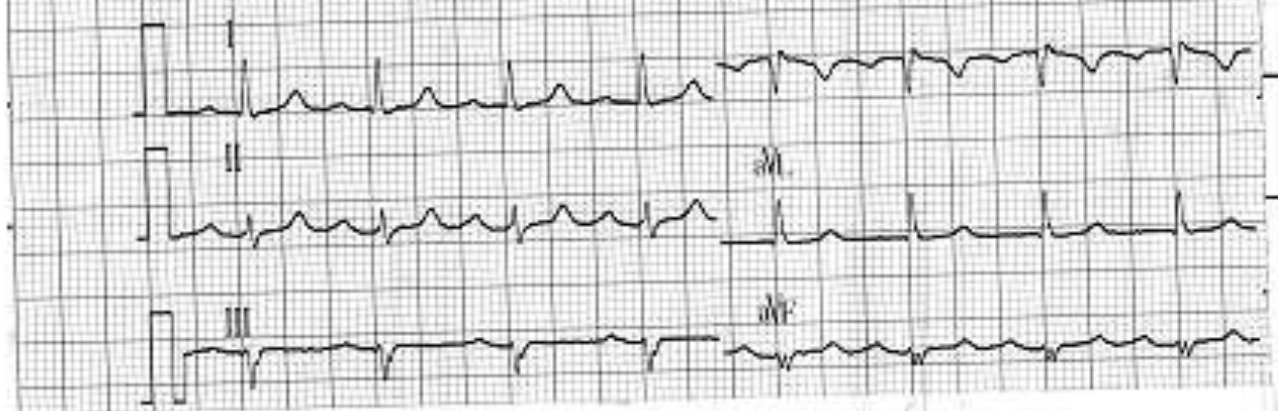


- RATE – 125bpm
- RHYTHM – normal sinus
- AXIS – Left axis
- (INTERVAL)
- HYPERTROPHY - none
- INFARCTION - none

- 
- CONCLUSION
 - SINUS TACHYCARDIA
 - LEFT ANTERIOR HEMIBLOCK

Mar-8-2011 20:25:09 ID:

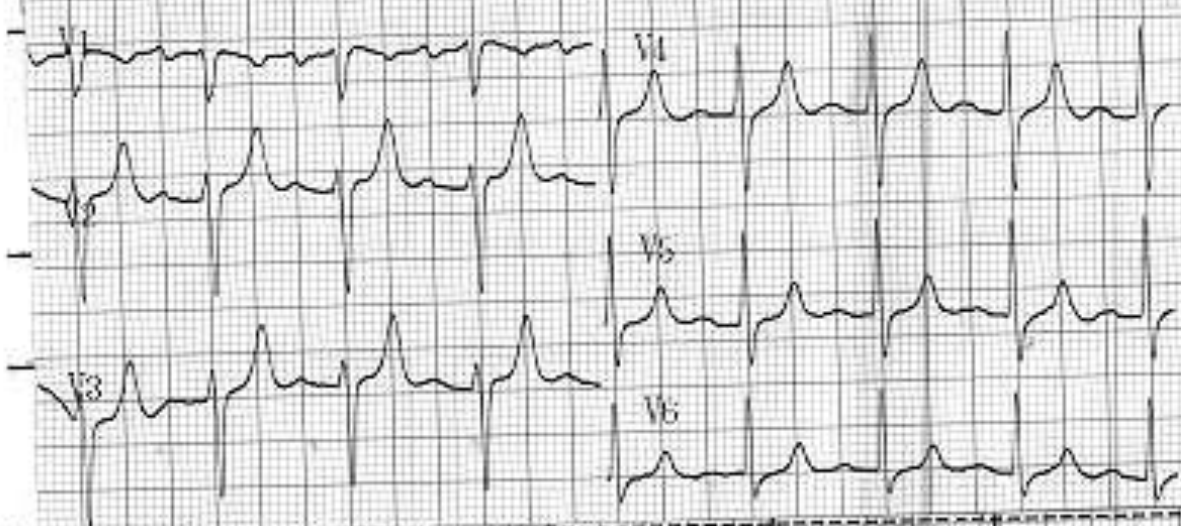
Tigbawan, Solomon Alabat 52/m



Mar-8-2011 20:25:09

Name:

HR:100



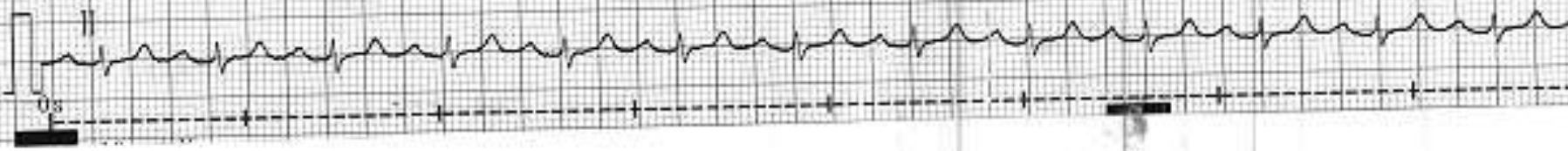
10mm/mV

25mm/s

10mm/mV

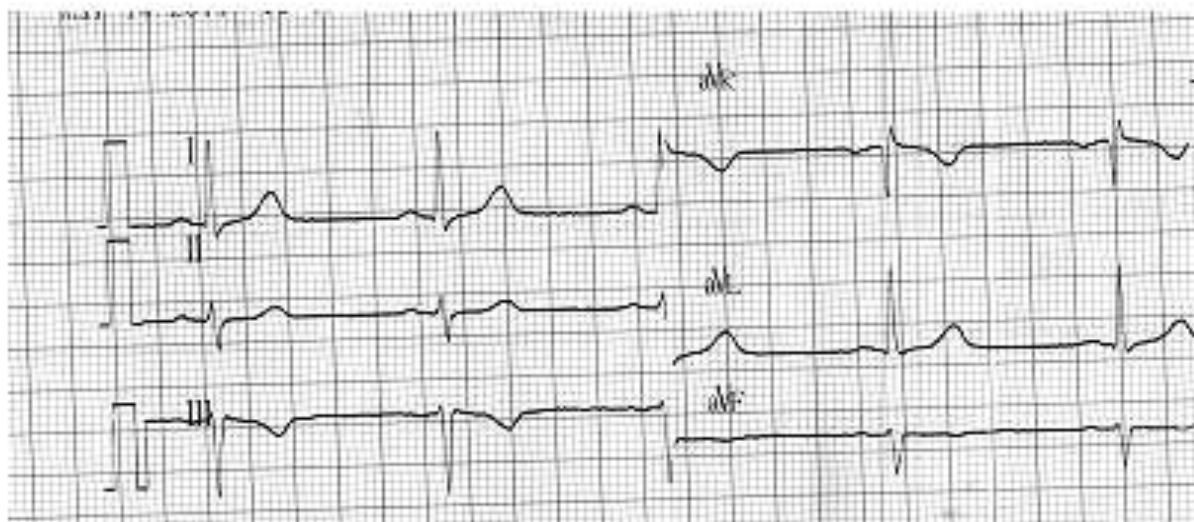
10mm/mV

10mm/mV

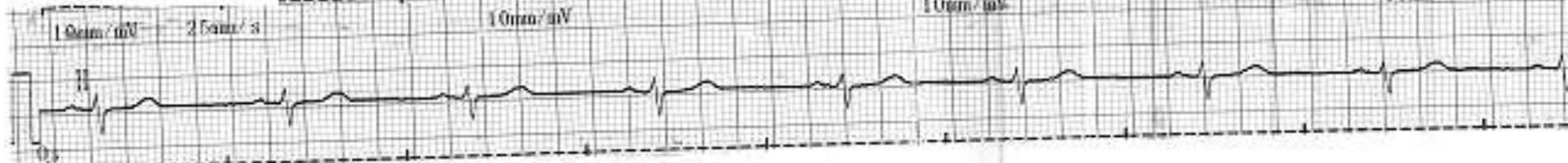
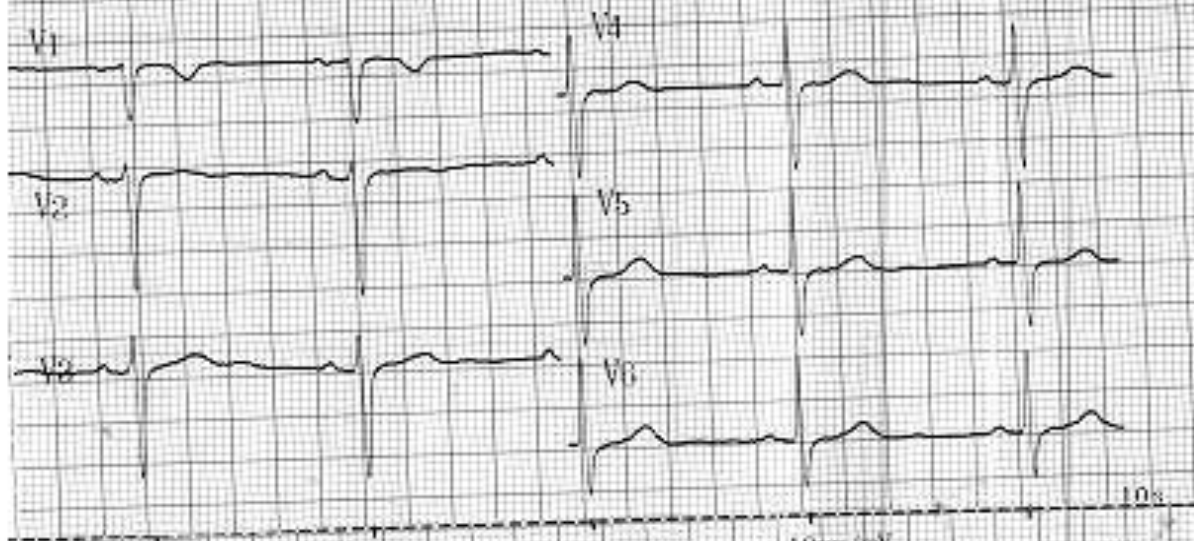


- RATE – 107bpm
- RHYTHM – normal sinus
- AXIS – normal axis
- (INTERVAL)
- HYPERTROPHY - none
- INFARCTION - none


- CONCLUSION
- SINUS TACHYCARDIA
- POOR R WAVE PROGRESSION V_1-V_3
- PEAKED T WAVES V_2-V_4



May 14 2011 10:48:43 Name: CIRIA, Alberto PD OP HR: 58



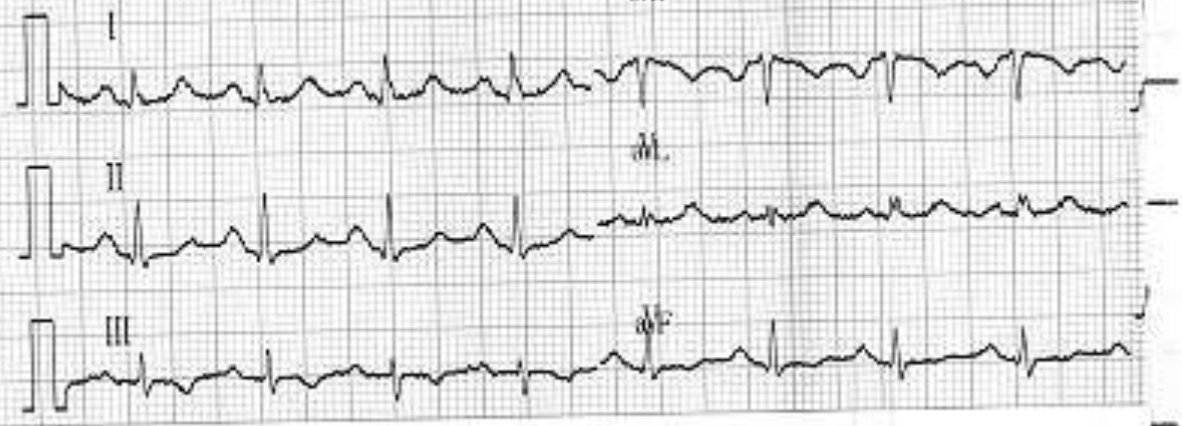
- RATE – 58bpm
- RHYTHM – normal sinus
- AXIS – left axis
- (INTERVAL)
- HYPERTROPHY - none
- INFARCTION - none

- 
- CONCLUSION
 - SINUS BRADYCARDIA
 - LEFT AXIS DEVIATION

Feb-8-2011 10:57:50 ID:

Ligbas, Purita Avila 69/F

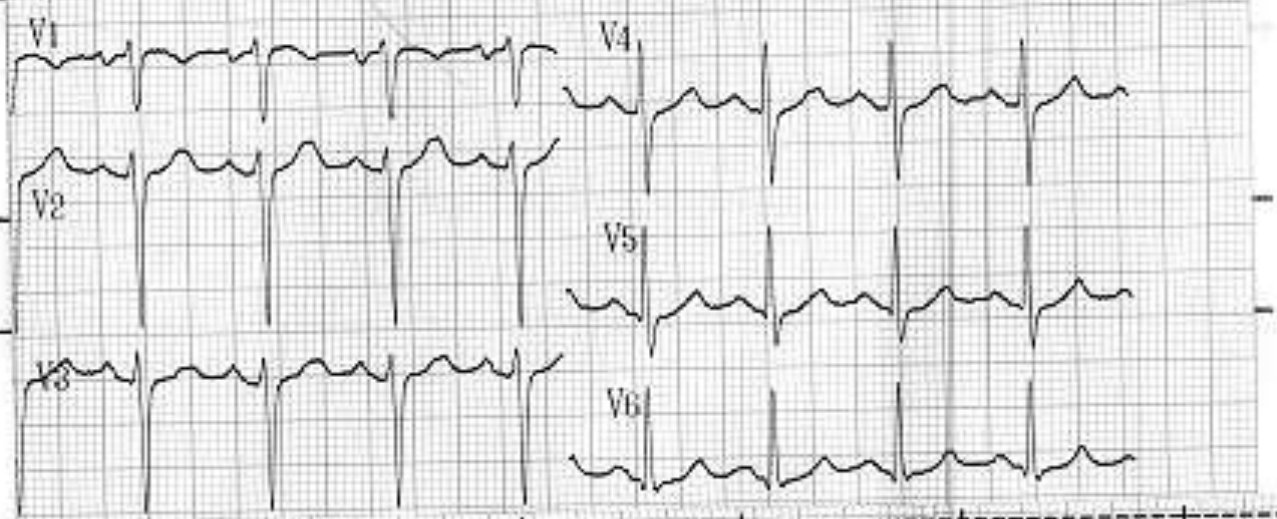
avk



Feb-8-2011 10:57:50

Name:

HR-104



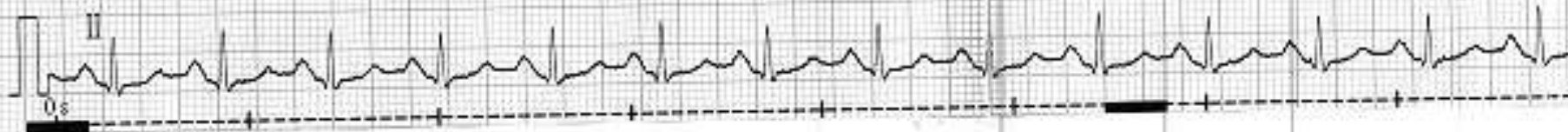10mm/mV

25mm/s

10mm/mV

10mm/mV

10mm/mV



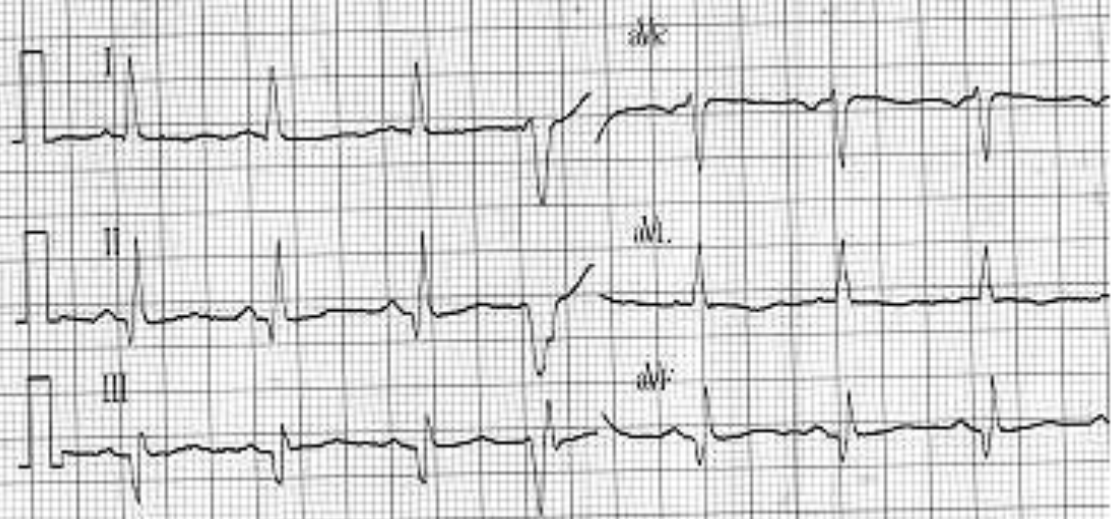
0s

- RATE – 107bpm
- RHYTHM – normal sinus
- AXIS – NORMAL axis
- (INTERVAL)
- HYPERTROPHY – LEFT ATRIAL ENLARGEMENT
- INFARCTION - none

- CONCLUSION
- SINUS TACHYCARDIA
- LEFT ATRIAL ENLARGEMENT
- POOR R WAVE PROGRESSION V₁-V₃

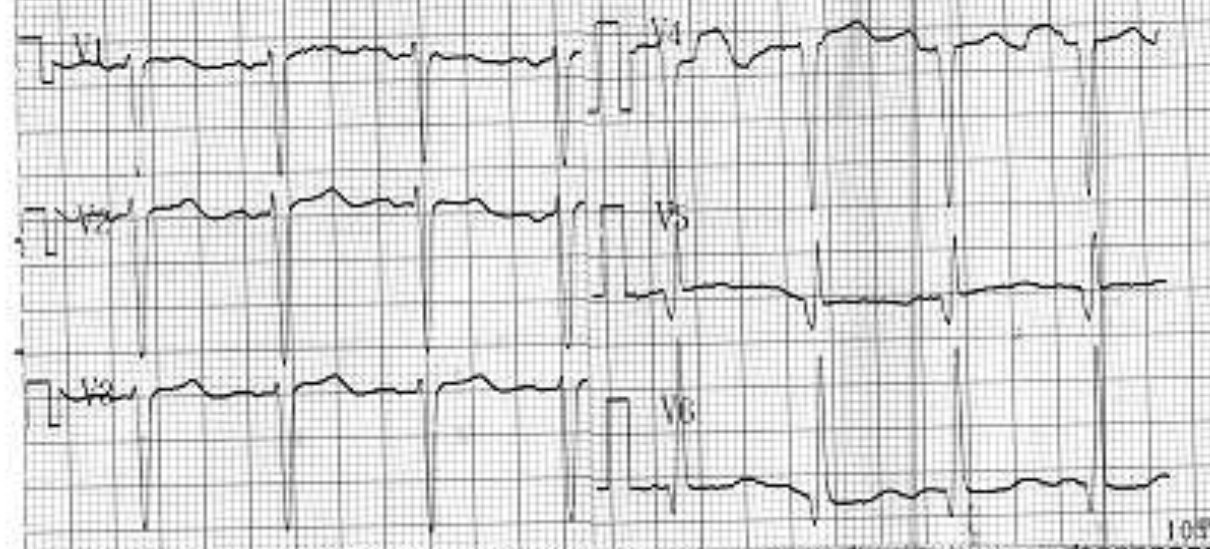
Feb-17-2011 13:41:01 ID:

Name: Male Age: years



Feb-17-2011 13:41:01

Name: CHADHO Kuse 100/100 HR: 96

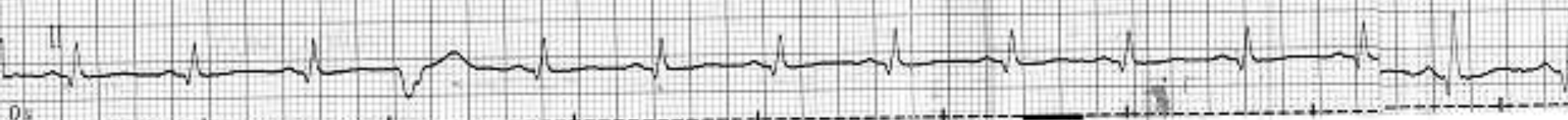


10mm/mV 25mm/s


10mm/mV

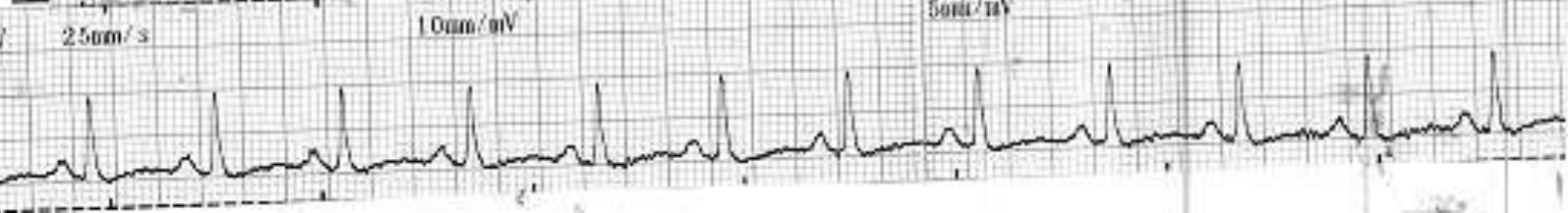
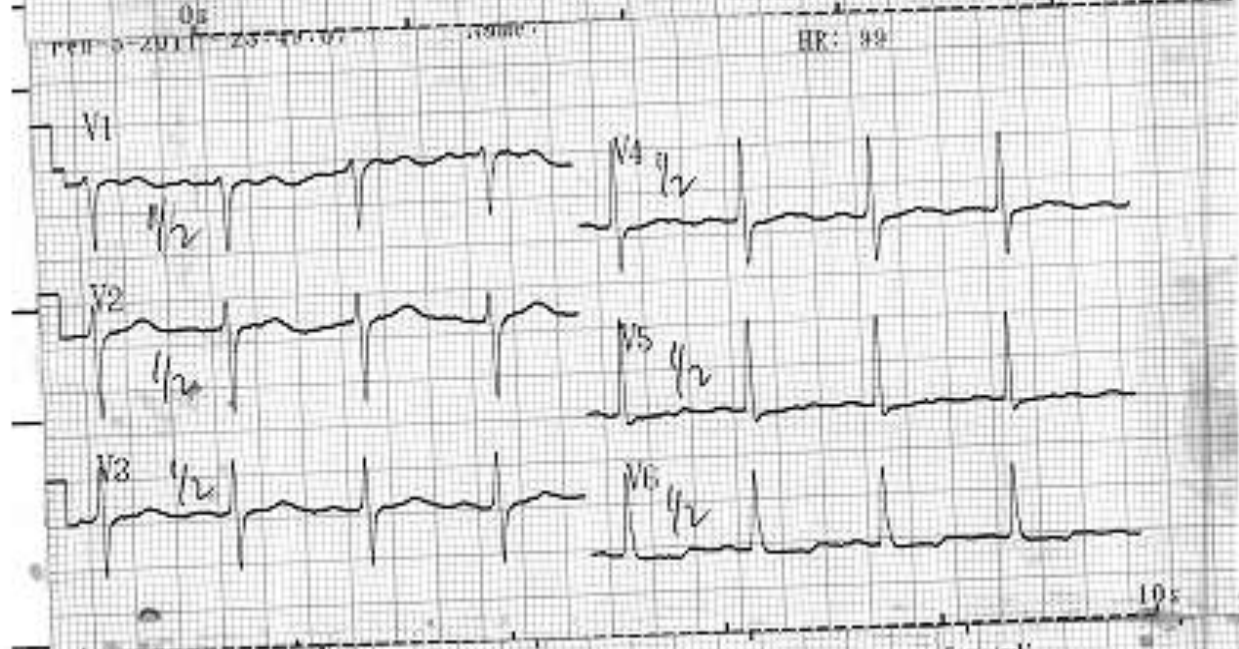
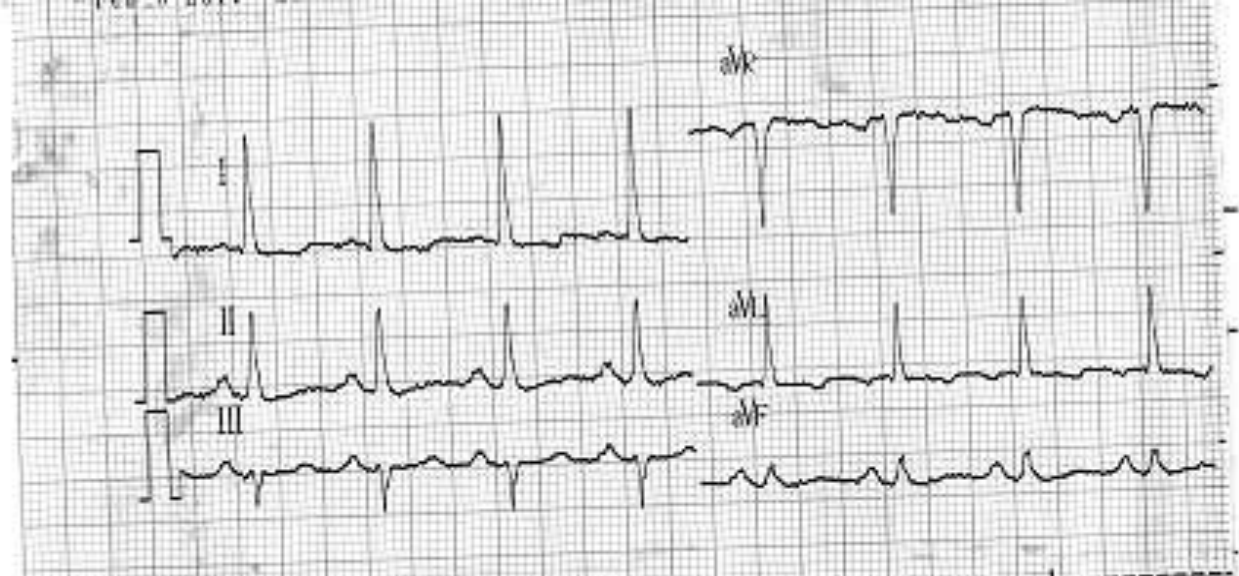
5mm/mV

10mm/mV



- RATE – 94bpm
- RHYTHM – normal sinus with PVCs
- AXIS – NORMAL axis
- (INTERVAL)
- HYPERTROPHY - none
- INFARCTION – II, III, aVF – q wave

- 
- CONCLUSION
 - Normal sinus rhythm with occasional premature ventricular contractions
 - Old inferior wall myocardial infarction



10mm/mV

25mm/s


10mm/mV

5mm/mV

5mm/mV

HR: 99

- RATE – 100bpm
- RHYTHM – normal sinus
- AXIS – NORMAL axis
- (INTERVAL)
- HYPERTROPHY - LVH
- INFARCTION – NONE

- 
- CONCLUSION
 - Normal sinus rhythm
 - Left ventricular hypertrophy
 - Non-specific ST-T wave changes